

A CASE STUDY OF PLACENTA PREVIA WITH PLACENTA PERCRETA

Akanksha Ved Prakash Pandey¹ & Dr. Manda Sanjog Ghorpade²

¹P.G Scholar, Department of Strirog Prasutitantra, MAM'S Sumatibhai shah Ayurvedic mahavidyalaya, Hadapsar, M.U.H.S, Pune, Maharashtra.

²H.O.D Guide, Department of Strirog Prasutitantra, MAM'S Sumatibhai shah Ayurvedic mahavidyalaya, Hadapsar, M.U.H.S, Pune, Maharashtra.

Abstract

Placenta percreta the rarest and most severe form of placenta accreta, can involve the urinary bladder. Because of its propensity for severe hemorrhage, it is a potentially life threatening condition. Although commonly diagnosed at the time of delivery, antenatal diagnosis may be achieved with ultrasound, magnetic resonance imaging and cystoscopy. Every attempt should be made to minimize potential for blood loss by avoiding removal of placenta at the time of delivery and either performing a hysterectomy or using methotrexate therapy to ablate the residual placenta in the post partum period.



Scholarly Research Journal is licensed Based on a work at www.srjis.com

INTRODUCTION

A women with placenta previa is potentially a source of anxiety for her care givers and her family members. Not knowingly when the anticipated antepartum hemorrhage might occur in hospital or at home, close to term or far from it. Beyond this it becomes more of concern when associated with placental abnormality placenta percreta. Placental abnormality in attachment namely: placenta accreta, increta and percreta. Amongst 3 percreta is the rarest and severe type.

Placenta accreta occurs when all or part of the placenta attaches abnormally to the myometrium. Three grades of abnormal placental attachment are defined according to the depth of invasion.

Accreta: chorionic villi attach to the myometrium rather than being restricted within the decidua basalis.

Increta: chorionic villi invade into the myometrium.

Percreta: chorionic vili invade through the myometrium.^{1,2} Among patients with histologic diagnosis of abnormal placental invasion 81.6% of cases were placenta accreta, 11.8 of cases were placenta increta, 6.6 were placenta percreta in one observational study.³

When the placenta is implanted partially or completely in the lower uterine segment it is called placenta previa . About one third of the antepartum haemorrhage belongs to placenta previa . The most characteristic event in placenta previa is painless hemorrhage , which usually does not appear until near the end of the second trimester . The incidence of placenta previa is around 1 in 300 deliveries .⁴ Prior cesarean delivery increases the likelihood of placenta previa .⁵ Incidence increases from 1.9% with 2 previous cesareans to 4.1 % with 3 or more.⁶ Also previous cesareans increases the chance of abnormal placental attachment particularly since the area of abnormal placental invasions are almost always in the area of the previous uterine scar. Alternatively, if placenta previa was present the risk for placenta accreta and was 3% at the first cesarean delivery and increased to 40% or more at the 3rd cesarean delivery. About 75% of the placenta percreta causes all are associated with placenta previa. Unlike the painless third trimester pre partum hemorrhage common with placenta previa, vaginal bleeding of placenta percreta is more likely to be painful due to invasion of the hemorrhaging placental tissue into the uterine wall.

CASE REPORT

A 24 Year old female with previous L.S.C.S presented at 31.5 week of gestation on 27 february 2019 with per vaginal painless bleeding and less fetal movements. Perinatal ultrasound done on 27 february 19 was suggestive of morbidly central placenta previa with EFW 1486gms and G.A 30.1 wks . Earlier also patient was admitted for the same complaint from 5/10/18 to 12/10/18 at S.G.A.K and was admitted at Sachi hospital 8 days ago. The patients obstetric history was significant for prior pregnancy delivered by cesarean and baby died on 3rd day of life due to febrile convulsions.

Patient got admitted and started with conservative as well as medicinal treatment to stop antepartum hemorrhage and after 2 days patients per vaginal bleeding stopped. Steroid 2 doses intra muscular given on 27/2/19 and repeated on 6/3/19.

Patient was indoor for observation of antepartum hemorrhage. On date 8/3/19 midnight 12:30 A.M patient had fever of 100 degree Fahrenheit and 101 degree Fahrenheit on 9/3/19 mid night 2:35 A.M . On 9th march 2019 morning patient started complaining of abdominal pain and Pain at L.S.C.S scar site. On examination patients

Pulse-104/min

Blood pressure- 100/70mmof hg

RR-18/min

S/E= RS-A_EB_E Clear

CVS –S₁S₂ Normal

Per abdomen – uterus ~ 32 wks counters not judged properly

Fetal heart sound -154/min regular

Contraction -2 for 20sec in 10 minutes .

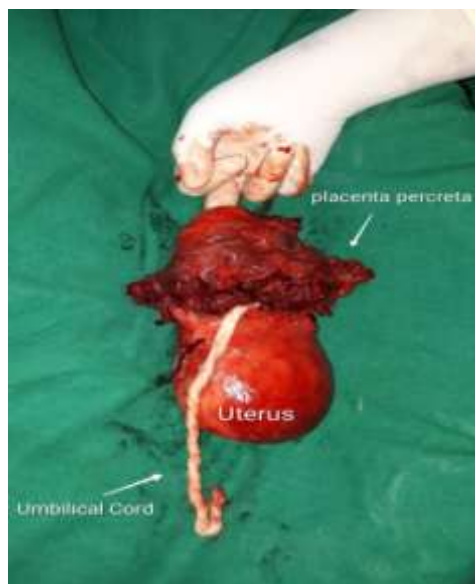
And scar tenderness was there.

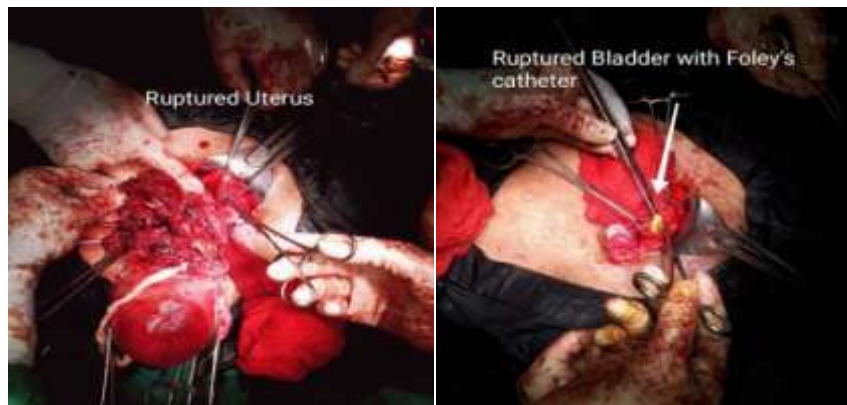Urgent ultrasound done –suggestive of central placenta previa with accreta .multiple anechoic lacunae of various size are noted within placenta S/O morbidly adherent placenta. Chages and extent of vascularity are S/O placenta accreta .EFW-1607gms ,AFI- 9-10cm,transverse lie. Scar thickness thickest 4.7mm.

Colour Doppler –umbilical artery showed loss of diastolic flow.

Fetal MCA showed reduced flow and RI values appear on higher side F/S/O Placento fetal insufficiency.

After ultrasound, decision of emergency cesarean taken and senior obstetrician, surgeon, paediatrician and anesthesiologist call given. After explaining patients present condition and prognosis to relatives, informed written high risk consent taken and immediately Patient taken to the operation theater and on opening patients abdomen fresh blood along with clots noted S/O ruptured uterus. Immediately without wasting time baby delivered, baby was alive with mild distress baby handed over to paediatrician.





After having close look it was clear that it was placenta percreta with central placenta previa. There was no way out to separate placenta from the uterus as lower uterine segment till cervix was fully invaded with placenta and there was no separate uterine wall seen. Immediately decision of obstetric hysterectomy was taken but before performing that it was necessary to prevent excessive blood loss which was achieved by ligating internal iliac arteries of both sides . After that when bladder was to be separated ,it was found that some part of placenta had been invaded into bladder. With the help of senior surgeon bladder was separated but as it was so adherent it got opened. After separating bladder completely bladder was sutured with vicryl 2-0 by senior surgeon in continuous interlocking pattern . When reached till vaginal vault some placental tissue noted at vault also. Specimen removed, abdomen closed layer wise and patient shifted to intensive care unit for close monitoring for 24 hours .

Intra operative management

II Packed cell volume

IV Fresh frozen plasma

I.V fluids II ringer lactate

I dextrose normal saline + inj. Diclofenac

Inj.methargin .2mg

Inj.carboprost 125mg intra myometrial

Inj. Pause 1gm IV

Inj. Pitocin 20 international units in 500ml RL

Inj.lasix 20mg IV

Inj.avil 22.75 mg IV

Inj.emset 4mg IV

Ing.dexamethasone 8mg IV

Post operative medicines

Inj. Ceftraixone 1gm IV B.D

Inj. Amikacin 500mg IV B.D

Inj. Metro 500mg IV T.D.S

Inj. Pan 40mg IV O.D

Inj. Emset 4mg IV T.D.S

Inj. Pause 1 gm IV 8 Hourly upto 24 hrs

Foleys catheter changed on 7th day and continued for 15 days. Pateint discharged on post operative day 9 with Foleys catheter in situ and oral antibiotic tablet Norflox TZ 1 B.D, oral hematinics and calcium supplements. Patient came on post operative 15th day to O.P.D, Foleys catheter clamped released and after confirming urine urge catheter removed .

DISCUSSION

Placenta accreta occurs in approximately one in 2500 pregnancies of these approximately 75% to 80% are placenta accreta ,about 17% are placenta increta and remaining 5% of so are placenta percreta. Although the over all incidence of placenta percreta is extremely low, the appearance of this rare disorder seems to be increasing due to the performance of more and more cessarian deliveries in past few years.

About 75% of placenta percreta cases are associated with placenta previa .⁷ Some patients with placenta percreta have even describe history of dull , continuous lower abdominal pain through out pregnancy.⁷ Evaluation to identify whether placenta percreta may be present includes ultrasound, magnetic resonance imaging and cystoscopy. Doppler ultra sonography will often reveal turbulent blood flow extending from the placenta to surrounding tissue .

During operative no intervention should be done until delivery of the baby has occurred once delivery has occurred , the presence of unstoppable uterine bleeding from the retained placental part should be controlled by ligating internal iliac artery and then obstetric hysterectomy should be performed.⁸However if uterine bleeding from retained placenta percreta is controlled after delivery , strong consideration for the use of methotrexate rather than any further surgical intervention should be considered. Conservative management with methotrexate should be performed with caution , however complication such as delayed bleeding and delayed hysterectomy should be considered.⁹In the presence of bladder wall

invasion and in the setting of uncontrolled uterine bleeding following the delivery, every attempt should be made to preserve the bladder.

CONCLUSION

Advancing maternal age, multiparity, prior cesarean section and prior abortions are independent risk factors for placenta previa. Placenta percreta which can affect the any neighboring uterine structure is a life threatening condition. When it involves the urinary bladder, a multidisciplinary approach utilizing a team of surgeons representing radiology, obstetric gynecology and urology is key to successful management. Every attempt should be made to achieve the diagnosis antenatally to minimize the blood loss, timely delivery in order to reduce the associated maternal and perinatal complications and to preserve the bladder.

REFERENCES

- Jauniaux, E, Jurkovic, D. *Placenta accreta: Pathogenesis of a 20th century iatrogenic uterine disease*. *Placenta*. 2012; 33:244-251. [PubMed] [Google Scholar]
- Jauniaux, E, Collins, S, Burton, GJ. *The placenta accreta spectrum: Pathophysiology and evidence-based anatomy for prenatal ultrasound imaging*. *Am J Obstet Gynecol*. 2017; pii: S0002-9378(17)30731-7
<http://doi.org/10.1016/j.ajog.2017.05.067>
- Wong Hs, Cheung YK, Zuccollo J, Tait J, Pringle K.C. *Evaluation of sonographic diagnostic criteria for placenta accreta*. *J Clin Ultrasound* 2008, 9:551-9. Case control level II-2.
- Martin JA, Hamilton B.E, Ventura SJ. *Births: Final data for 2001*. National Centre for Health Statistics 2002.
- Federiksen MC, Glassenberg R, Stika C.S. *Placenta previa: A 22 years Analysis*. *Am J Obstet Gynecol* 2009; 180:1432.
- Gesteland K, Oshiro B, Henry E. *Rates of placenta previa and placental abruption in women delivered only vaginally or only by cesarean section*. *J Soc Gynecol Investing*. 2004; 11:208.
- Abbas F, Talati J, Wasti S, et al. *Placenta with bladder invasion as a cause of life threatening haemorrhage*. *J Urol*. 2000; 164:1270-1274. [PubMed] [Google Scholar]
- Hudon L, Bel fort MA, Broome DR. *Diagnosis and Management OF Placenta percreta: a review*. *Obstet Gynecol sur*. 1998; 53:509-577. [PubMed] [Google Scholar]
- Hays AM, Worley KC, Roberts, SR. *Conservative Management of placenta percreta: experiences in two cases*. *Obstet Gynecol*. 2008; 112:426. [PubMed] [Google Scholar]